

Malt lymphoma associated with Sjögren Syndrome: clinical report

Susana Magalhães, Sónia Pereira, Isabel Bessa, Fátima Guedes, Amélia Pereira

Abstract

Sjögren Syndrome is considered an autoimmune disease of the exocrine glands, which involves especially the salivary and lachrymal glands. The clinical manifestations are wide, and can only be clearly shown by dryness of the oral and conjunctival mucosa or by articular, lung and/or renal involvement.

One third of the patients with this syndrome present systemic manifestations including B cells lymphoma, namely the MALT lymphoma of the Sjögren' target-organs. In spite of its scarcity and its slow course, the patients have a worst prognosis in relation to the other type of MALT lymphoma, due to its tendency to dissemination and inherent therapeutic implications.

A case of a 64 years old male patient coming from the Oncology consultation is reported, with MALT lymphoma initial

diagnosis, shown after the right parotid gland excision which was due to recurrent parotiditis episodes. Once the patient presented oral and conjunctival dryness complaints, SS-A(Ro) e SS-B(La) autoantigens were determined and Schirmer's I test was performed, its positive values confirm the Primary Sjögren Syndrome diagnosis.

Due to xerostomia and MALT lymphoma coexistence, chemotherapy treatment with CHOP protocol was chosen.

The scarcity and singularity of this case study have led the authors to its publication.

Key words: Sjögren Syndrome, B cells Lymphoma, MALT Lymphoma, Parotid gland, Xerostomia.

Introduction

Sjögren Syndrome (SS) is a chronic auto-immune disease with a slow progress, featured by lymphocytary infiltration of exocrine glands, involving mainly the salivary and lachrymal glands. Its clinical spectrum is variable, and can be limited to xerostomia and/or conjunctival dryness, or manifest itself with systemic involvement showing a joint, pulmonary or kidney dysfunction. From the baseline and unspecific manifestations to the full condition can take from 8 to 10 years.

This disease can occur isolate and be called Primary (prevalence around 1 to 3 % of the population),¹ or it can occur associated with other auto-immune rheumatic diseases (being expressed in 30% of these patients), usually lupus and rheumatoid arthritis, being called Secondary.

The disease is mainly expressed in female patients (ratio 9:1) with an average age at diagnosis of 50 years old.²

Most cells characterizing the tissue infiltrate of exocrine glands (60-70%) is TCD₄ lymphocytes and only a minority of B lymphocytes; however, there is a hyper-reactivity, producing oligo-monoclonal immunoglobulins IgM and IgG. The auto-immune response is directed to ribonucleoproteins Ro/SS-A and La/SS-B, being the first an auto-antigen consisting in two polypeptides of 52 and 62 kDa linked to a cytoplasmatic RNA, and the second a nuclear protein of 48kDa, linked to the transcription of RNA-polymerase III. These auto-antigens are associated with the early disease onset, its higher increase, salivary glands hypertrophy, severity of the lymphocytary infiltration of smaller salivary glands and extra-glandular manifestations. The mechanism responsible for the auto-immune process is the epithelial cells apoptosis.^{3,4}

The clinical condition is dominated by a dryness of the oral mucosa (xerostomia) and ocular (dry keratoconjunctivitis). Patients have difficulty swallowing and in conversation, increase in dental caries, feeling of an ocular foreign body, burning feeling and ocular fatigue, reduced tears and photosensitivity. It can also exist an involvement of other exocrine glands, with a

Department of Medicine.
Hospital Figueira da Foz, EPE

Received for publication on the 13th February 2007

Accepted for publication on the 29th July 2009

TABLE I

Systemic manifestations associated to Sjögren syndrome

Skeletal muscle	Arthralgia (53) Myalgias (12)
Cutaneous	Dry skin (66) Purpura (15) Vasculitis (11)
Pulmonary	Xerotrachea (66) Pulmonary infiltrate (20)
Gastrointestinal	Esophagic dysmotility (90) Pancreatitis (5) Hepatitis (38-72)
Renal	Renal tubular acidosis (12) Interstitial nephritis (12)
Neurology (11)	Peripheral neuropathy CNS involvement
Hematology	Anemia (6) Leukopenia (22) Lymphoma (5-10)

The numbers in brackets correspond to an average percentage.
Adapted from: Carsons S. A review and update of Sjögren's Syndrome: manifestations, diagnosis and treatment. *Am J Manag Care.* 2001;7, 433-443.

reduced secretion of the mucosa glands of the upper and lower breathing tree, with a mucosa dryness in the nasopharynx and trachea (xerotrachea) and the gastrointestinal mucosa glands, with atrophy of the esophagic mucosa, atrophic gastritis and subclinical pancreatitis.

The extraglandular manifestations are seen in 33% of SS patients, however its occurrence is rarer in the syndrome associated to rheumatoid arthritis. Systemic manifestations can include vasculitis, auto-immune hepatitis, pulmonary fibrosis, central nervous system involvement, renal tubular acidosis and non-Hodgkin lymphoma (NHL)⁵ (Table I).

The absence of a definitive exam or "gold-standard" in SS, has created a diversity of studies with different diagnosis criteria, making difficulty to interpret data in international literature. Recently, a multicentre study made in 12 countries, guided by the Study Group of the European Community on criteria for the Diagnosis of Sjögren Syndrome, and currently improved by an European and American Study Group, has proposed a classification with a 95% sensitivity/specificity, with a significant interest

TABLE II

Diagnosis criteria of the Sjögren Syndrome, according to the American-European Consensus Group

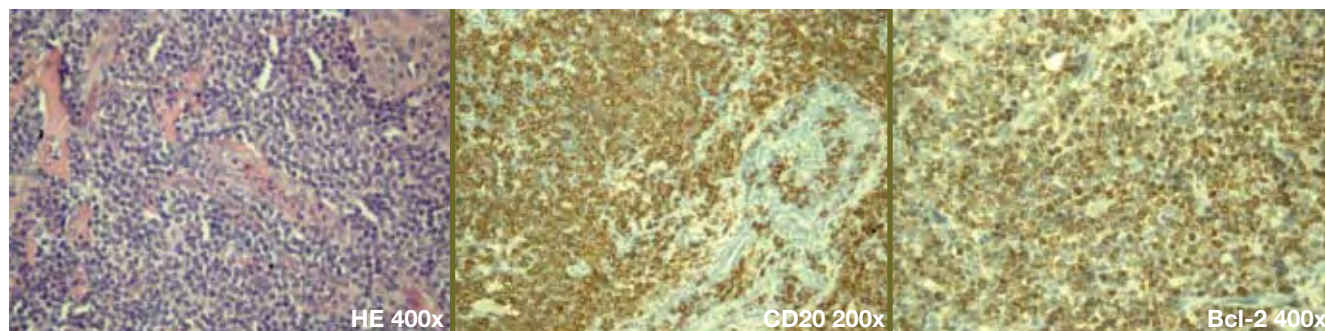
I. Ocular symptoms reducing tears
II. Oral symptoms of reduced salivation
III. Signs of ocular involvement Schirmer I Test (< or = 5 mm in 5 min) Rose Bengala (> or = a 4)
IV. Histopathology: 1 or more foci (agglomerate of 50 or more inflammatory cells) in a smaller salivary gland biopsy)
V. Involvement of the salivary gland Salivary scintigraphy Parotide sialogram Sialometry with a non stimulated salivary flow < or = a 1,5 ml in 15 min
VI. Antibodies anti Ro (SS-A) e/ou La (SS-B)
Exclusion criteria: anterior radiotherapy of head and neck, C hepatitis, AIDS, pré-existing lymphoma, sarcoidosis, graft disease vs host, use of anticholinergic.
Primary Sjögren syndrome: four of the six, since than IV item (histopatology) or VI (serology) is positive, or three of the four items of objective criteria (III, IV, V or VI).
Secondary Sjögren syndrome: presence of item I or II, more two between items III, IV and V.

in clinical practice^{1,6} (Table II).

SS treatment has the objective of a symptomatic relief of xerostomy and dry keratoconjunctivitis, refilling the absent secretions. It should be avoided the use of drugs causing tear and salivary hypofunction, as diuretics, anti-hypertensive and anti-depressants drugs. Pilocarpine (5 mg 3id) and cevimeline (30 mg 3id) improve complaints and are well tolerated. Hydroxichloroquine is useful in arthritis and glucocorticoids (1 mg/Kg/day) and/or immunosuppressants, as cyclophosphamide, are indicated in the treatment of systemic vasculitis.

NHL is, in general, the more severe complication in SS patients, and its early detection must be a priority task to those who are treating these patients. It was estimated that a Primary SS patient has a risk of having a NHL 16 times higher.⁷ Lymphomas have, in its majority, origin in extranodal B cells, namely salivary glands, and can also occur in the gastrointestinal tract, lung, thyroid.

The significant increase on size of salivary glands



Anatomic pathology result of the surgery piece (right parotid), with a HE staining and immunohistochemistry studies.

FIG. 1

(namely if there is a dominant mass) and the emergence of peripheral adenopathies, splenomegaly or pulmonary infiltrates are suggestive signs of lymphoproliferation. Also the longitudinal monitorization of laboratorial endpoints may be suggestive of NHL development, as a detection of monoclonal protein, leukopenia, anemia and a loss of specific antibodies previously present (ANA and anti-SSA/B).⁸ A recent study shows that low levels of C_4 and cryoglobulinemia increase the risk of NHL.⁹

Several histologic subtypes of NHL were described in SS, including follicular lymphomas, of big cells, immunoblastic and MALT lymphomas (“mucosal-associated lymphoid tissue”).¹⁰ MALT lymphomas are, according to some authors, 46-56% of all malignant lymphomas in SS.^{10,11} MALT lymphoma is originated in cells with post-follicular differentiation, in environments of persistent antigenic stimulation, as happens in an auto-immune process. The primordial locations for MALT lymphomas are the SS target-organs, the salivary glands and the ocular annexes, with a particular incidence in the parotid gland.⁹

The NHL expected treatment associated to SS it does not differ from the standard treatment; however, if chemotherapy shows medullary toxicity and other systemic effects, radiotherapy induces painful complaints, exacerbating previous xerostomia and ocular dryness typical of SS.¹²

In spite of the slow evolution of MALT lymphoma, the disease tends to progress and spread in the surveillance period,¹³ and the more important prognosis factors are the histologic transformation and the patient's age.¹⁴

Clinical case

A 64 years old man, seen as an outpatient in the Medical Oncology Service of Figueira da Foz, EPE in December 2004, by a non-Hodgkin lymphoma, MALT type, of the right parotid identified after parotidectomy. The patient was already followed in a Surgery Consultation, since 2001, due to parotiditis recurrent episodes (five in total), with bi- or unilateral attainment, having been subject to two aspiration punctures, but without enough material for diagnosis. After exeresis of the right parotid, in September 2004, complicated in the post-surgery period with abscess of the surgical cavity, the anatomic pathology of the piece has revealed involvement by a non Hodgkin lymphoma, MALT type (Fig. 1).

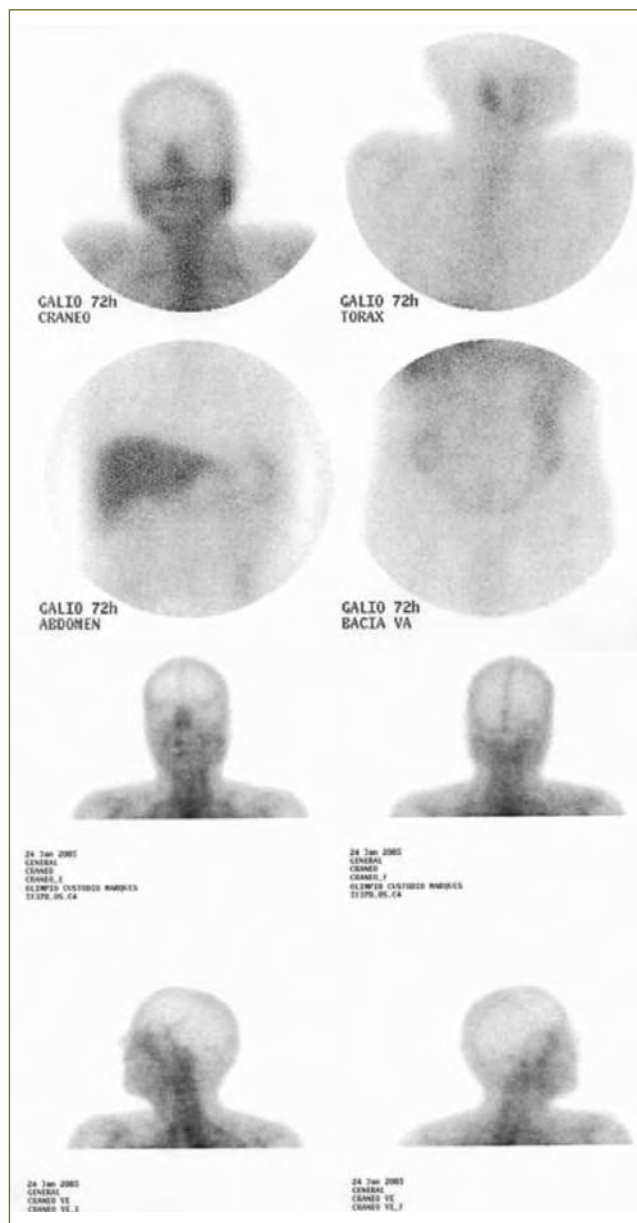
In the anamnesis, the patient mentioned complaints of oral mucosa dryness, with trouble swallowing, frequent conjunctival burning and photophobia with years of evolution. He denied paleness, asthenia, blood dyscrasia or any adenopathies.

In the pathologic background it was mentioned infections in the upper airways, major depressive disorder (having been admitted for 6 months), vitiligo and prostate benign hyperplasia. Apart of the parotidectomy the patient had been subject to hernia repair and safenectomy.

The patient mentioned smoking habits of 20 number of packs per year, with a 10 years evicton, ingesting around 20 gr of alcohol/day and it was medicated with paroxetine 20 mg id and ethyl loflazepate 2 mg id.

The family background was irrelevant.

He was a resident in a house with water, electric-



Pre-treatment scintigrams.

FIG. 2

ity and sanitation. Denied contact with animals and recent trips.

At the objective exam he was conscious, cooperating, oriented in time/space, with a coinciding real and apparent age. The patient was afebrile and normotensive, with normal vital signs. His weight was 62 Kg, 1,71 m height (BMI – 23.7 Kg/m²). Mucosae were coloured and hydrated. No peripheral adenopathies were evident. The neck palpation identified

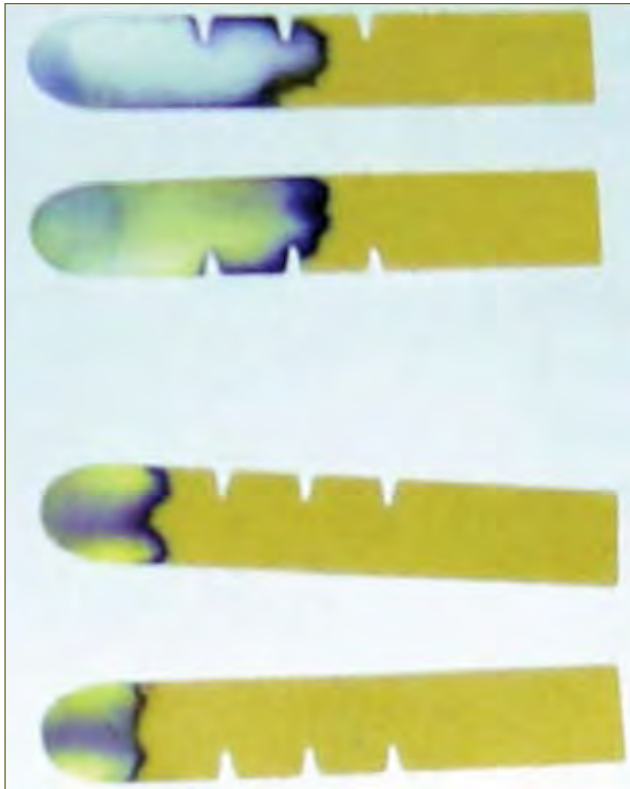
a right submandibular node (compatible with post-surgical fibrosis) and the thyroid was not palpable. The cardiopulmonary auscultation did not show changes, the abdomen was soft, depressible, painless and without apparent organomegaly. There were no evident changes in the summary neurologic exam. The patient has shown cutaneous lesions of scattered vitiligo, with a preferential involvement in the trunk and upper limbs.

In summary, apart from non Hodgkin lymphoma, MALT type, of the known right parotid gland and the vitiligo, the patient presented a xerostomia clinic and dryness of ocular mucosa, having been put forward the following diagnosis hypothesis: antidepressant secondary effects? Sjögren syndrome? Several supplementary tests were performed then with a view to clarify the condition and the stage of the type MALT lymphoma.

The hemogram did not show any changes and the erythrocyte sedimentation rate was 12 mm in the 1st hour. The blood biochemistry presented normal values, with C reactive protein of 1 mg/L and lactic dehydrogenase of 278 UI/L. The β 2-microglobulin dosage was 1344,3 μ g/l (700-3400). The electrophoretic proteinogram did not record changes, as well as the quantification of immunoglobulin (IgG-1356 mg/dL, IgA-365 mg/dL, IgM-132 mg/dL). Viral hepatitis and HIV markers were negative and the hormone dosage in the thyroid tests did not show any changes.

The patient was subject to computerized axial tomography, that did not show any changes, namely adenopathies in the cervical region and the mediastine, hilar and abdominal ganglionic chains. The myelography did not reveal any invasion of the spinal cord by lymphomatous cells and spinal cord phenotypes showed a normal phenotypic study of the B lymphocytes. Two body scintigraphies were performed with the administration of gallium 67 and white blood cells marked by technetium (Fig. 2), revealing both an hyperfixation area located in the left parotid, suggesting a probable lymphoproliferative process in evolution. The aspiration puncture of the left parotid, performed to identify the contralateral involvement, showed only purulent material, inflammatory cells and histiocytic cells, compatible aspects with sialadenitis, without visualizing any lymphomatous cells.

The auto-immunity study was negative for all tested antibodies (Abs Anti SM, Abs Anti RNP, Abs Anticentromer, Abs Anti SCL 70, Abs Anti Jo-1,



Comparison between the patient's Schirmer test (below) and another normal result (above).

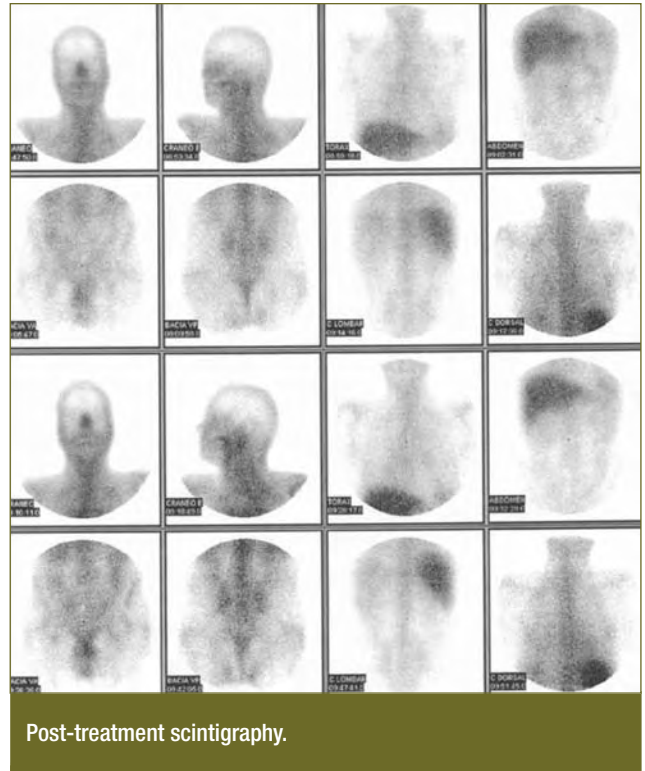
FIG. 3

Abs Anti-ribosomal and Abs Anti-histones), with exception of Abs Anti SS-A(Ro) and Abs Anti SS-B (La) which were positive in different determinations. The Schirmer I test was positive, aiming the reducing of the lachrymal secretion (Fig. 3).

The definitive diagnosis established were: Sjögren Primary Syndrome and Non Hodgkin Lymphoma, type MALT, of the parotid, with a IIE staging, following Ann-Harbor classification and a intermediary-low risk, according to the "International Prognostic Index" (IPI – two risk factors: age above 60 years of age and extranodal involvement in two areas).

The patient started a treatment to lymphoma with chemotherapy, fulfilling four cycles according to the CHOP protocol (cyclophosphamide, adriamicine, vincristine and prednisona). The administration of carbomer collyrium and pilocarpine tablets in the conventional doses, being referred to Ophthalmology.

After finishing chemotherapy, the patient repeated the head and neck scintigraphy with gallium 67 (Fig. 4), showing a significant reduction of the radiodrug at



Post-treatment scintigraphy.

FIG. 4

the left parotid level. A thorax X ray and an abdominal ultrasound were made, showing no changes, and the CAT scan was not an option considered due to the normality before treatment.

The patient was kept in regular surveillance in the outpatient consultation of Oncology of the District Hospital of Figueira da Foz, EPE.

Discussion

This case raises several interesting points for discussion, apart of the inherent diagnostic rarity, also because it is about a male patient, where the SS has a smaller expression. The SS association with vitiligo is interesting, and might be revealing of a more generalized manifestation of auto-immunity, without knowing other published cases.

The IPI staging and classification made in the lymphoma were controversial, as, in spite of the initial scintigraphy made being suggestive of the lymphomatous involvement of the left parotid, this was never documented resorting to Anatomic Pathology and aspiration puncture of the parotid gland is in no way a sensitive detection method. In fact, an increase in the capture of radioactive products can only be due

to the typical SS glandular chronic inflammation and its intensity can change overtime, what can justify the reduction on the radiodrug fixation after treatment. However, knowing that the IE staging (only right parotid) or IIE (both parotids) it does not imply changes in the therapeutic modality more indicated to this case, it was not made a biopsy or contralateral exeresis for a definitive anatomic pathology study.

For this case, the possible therapy options were chemotherapy and radiotherapy but as it was mentioned before, the exacerbation of xerostomia and ocular dryness inherent to the latter directed the choice of chemotherapy.

It is to be highlighted the fact that the diagnosis path was not the ideal one in this case, as the SS was only recognized after identifying the MALT lymphoma, in spite of the xerostomia clinic and ocular dryness to present a significant evolution. Once again, it is important to highlight the appropriate SS diagnosis in earlier stages enables the clinical follow up of the possible complications. ■

References

- Vitali C, Bombardieri S, Moutsopoulos HM. The European Community Study Group On Diagnostic Criteria For Sjögren's Syndrome-Preliminary criteria for Sjögren's Syndrome. *Arthritis Rheum* 1993; 36:340-347.
- Bell M, Askari A, Bookman A, Frydrych S, Lamont J, McComb J, Musclop C, Slomovic A. Sjögren's Syndrome: a critical review of clinical management. *J Rheumatol* 1999; 26:2051-2061.
- Tapinos NI, Polihronis M, Tzioufas AG, Moutsopoulos HM. Sjögren's Syndrome: autoimmune epithelitis. *Adv Exp Med Biol* 1999; 455 : 127-134.
- Manganelli P, Fietta P. Apoptosis and Sjögren's Syndrome. *Semin Arthritis Rheum* 2003 ;33(1):49-65.
- Carsons S. A review and update of Sjögren's Syndrome: manifestations, diagnosis and treatment. *Am J Manag Care* 2001;7: 433-443.
- Vitali C, Bombardieri S, Jonsson R, Moutsopoulos HM, Alexander EL, Carsons SE, Daniels TE, Fox PC, Fox RI, Kassan SS, Pillemer SR, Talal N, Weisman MH; European Study Group on Classification Criteria for Sjögren's Syndrome. Classification criteria for Sjögren's syndrome: a revised version of the European criteria proposed by the American-European Consensus Group. *Ann Rheum Dis* 2002;61(6):554-558.
- Theander E, Henriksson G, Ljungberg O, Mandl T, Manthorpe R, Jacobsson LT. Lymphoma and other malignancies in primary Sjögren's syndrome: a cohort study on cancer incidence and lymphoma predictors. *Ann Rheum Dis* 2006; 65(6):796-803.
- Zulman J, Jaffe R, Talal N. Evidence that the malignant lymphoma of Sjögren's Syndrome is a monoclonal B cell neoplasm. *N Engl J Med* 1978; 299: 1215-1220.
- Skopouli FN, Dafni U, Ionnidis JP, Moutsopoulos HM. Clinical evolution, and morbidity and mortality of primary Sjögren's Syndrome. *Semin Arthritis Rheum* 2000;29: 296-304.
- Voulgarelis M, Dafni UG, Isenberg DA, Moutsopoulos HM. Malignant lymphoma in primary Sjögren's syndrome: a multicenter, retrospective, clinical study by the European Concerted Action on Sjögren's Syndrome. *Arthritis Rheum* 1999;42:1765 -1772.
- Royer B, Cazals-Hatem D, Sibilia J et al. Lymphomas in patients with Sjögren's syndrome are marginal zone B-cell neoplasms, arise in diverse extranodal and nodal sites, and are not associated with viruses. *Blood* 1997;90:766 -775.
- Stewart A, Blenkinsopp PT, Henry K. Bilateral parotid mucosa-associated lymphoid tissue lymphoma and Sjögren's syndrome. *Br J Oral Maxillofac Surg* 1994;32:318 -322.
- Tonami H et al. Mucosa-associated lymphoid tissue lymphoma in Sjögren's syndrome: initial and follow-up imaging features. *Am J Roentgenol* 2002;179(2):485-489.
- Ambrosetti A et al. Most cases of primary salivary mucosa-associated lymphoid tissue lymphoma are associated either with Sjögren syndrome or hepatitis C virus infection. *Br J Haematol* 2004 ;126(1):43-49.