

Synchronous multiple neoplasms: a clinical case with unusual presentation

Mário Amaro*, Manassas Neto**, Henrique Santos***, José Barata***, Marques Ferreira****, Álvaro de Carvalho*****

Abstract

The authors present the case of a 79-year-old man with a diagnosis of K light-chain multiple myeloma and gastric adenocarcinoma, as synchronous neoplasms, which is considered an unusual association in the literature reviewed.

They also perform a review of the etiopathogenic mechanisms of primary multiple neoplasms.

Key words: multiple neoplasms; synchronous neoplasms.

Introduction

The term Multiple Primary Neoplasms (MPN) refers to the occurrence, in the same individual, of two or more malignant neoplasms involving the same organ or different organs.¹

Chronologically, multiple neoplasms whose clinical translation is manifested in a period of less than six months are designated synchronous, and those with a longer diagnostic interval are designated metachronous.²

This interesting topic, addressed for the first time by Bilroth about a hundred years ago¹, has been the subject of countless studies, particularly from an epidemiologic and etiopathogenic perspective, and its incidence has progressively increased.^{2,3,6}

Due to the diagnostic challenges that it often produces, and the complex therapeutic options that it frequently demands, the exhaustive disclosure of new cases of multiple neoplasms, either in isolation or as part of casuistic studies, will certainly contribute toward a better knowledge of this condition.

Clinical case

MCL, 79-year-old White male, a retired bricklayer, born in Vila Nova de Paiva, resident in Casal do Marco, admitted to the Medical Service II of Hospital

Garcia de Orta on the 24th December 93, with bone pain and diffuse osteolytic lesions in the skeletal radiographies.

Two months before hospitalization, he began to experience lumbago and pain in the right coxofemoral joint with functional limitation.

He was medicated in an outpatient environment with non-steroidal anti-inflammatory drugs, without any improvement.

Onset of asthenia, anorexia and exacerbation of right coxalgia in the week preceding hospital admission, after a fall, with clearly evident claudication that obliges the patient to spend most of the time in bed.

Due to the persistence of pain, the patient came to the Emergency Care Service, where he underwent a radiological study of the pelvis, which showed multiple osteolytic lesions. While still in Emergency, he had radiographies of the skull and long bones in which identical lesions were detected, and he was hospitalized for clarification of the condition.

He had no other complaints in other apparatus or systems.

Personal history included arterial hypertension and moderate alcohol consumption (<80g of alcohol / day). Non-smoker.

No facts of relevance in the family history.

Upon objective examination, the patient appeared alert, not very collaborative, prostrate, emaciated, eupnoeic and apyretic, with slightly discolored skin and mucous membranes.

At the level of the left posterior cervical triangle, extending to the left supraclavicular fossa, it was possible to palpate a hard, petrous tumor, painless, with poorly defined borders, adhering to the deep planes,

*Resident to the Supplementary Internal Medicine Residency

**Public Health Resident

***Hospital Assistant of Internal Medicine

****Senior Hospital Assistant of Internal Medicine

*****Director of the Department of Medical Specialties

Hospital Garcia de Orta, Almada

with a maximum diameter of around 8 cm.

On palpation, the thyroid was not enlarged, and there were no cervical adenopathies or adenopathies of other chains.

In the examination of the limbs, there was intense pain on palpation and mobilization of the right coxofemoral joint, with extreme walking difficulty and claudication.

The remaining objective exams, namely the cardiopulmonary and abdominal exams and rectal palpation, did not reveal any changes.

From the laboratory exams performed, the following results are highlighted:

Hb 11.5 g/ml; leucocytes 11 800 mm³ - (N 70%); platelets 246,000 mm³; ESR 130mm / 1st hr.; urea 127 mg/dl; creatinine 1.7 mg/dl; calcium 14.9 mg/dl; alkaline phosphatase 120 U/l; uric acid 10.4 mg/dl; TP 72%; APTT 31.1 s; CEA 22; β2 microglobulin 8.8mg/dl; total proteins 6.5 mg/dl, with increase of fractions α2 and in electrophoresis.

Immunoglobulin levels (IgA, IgD, IgG, IgM) – normal. Bence-Jones proteinuria-positive.

Serum protein immunofixation revealed the presence of free-K light chains and the absence of heavy chains of IgA, IgG and IgM. The presence in the serum of heavy chains of IgD was also excluded by immunofixation. In the urine, immunofixation showed K light chains.

The skeletal radiography (Figs. 1A and 1B) exhibited diffuse osteolytic lesions, dispersed around the

skullcap, right humerus, bilateral ribcage, pelvis, right femur and right tibia.

Myelogram: inconclusive due to deficient harvesting.

Upper digestive endoscopy: “ulcer with polypoid edges and signs of non-active hemorrhage, located in the gastric fundus, which was biopsied”, the gastric biopsy being compatible with “poorly differentiated adenocarcinoma”.

Bone biopsy: “hypercellular osteomedullary biopsy causing diffuse infiltration consisting of 92% of plasmocytes with eccentric nuclei and clumping chromatin, aspects that are compatible with myeloma”.

Biopsy of the supraclavicular lesion: “plasmocytary infiltrate with identical characteristics to those described in the bone biopsy”.

Cervical CAT scan showed “voluminous expansive lesion involving the left supraclavicular region, extending over the upper part to the hyoid plane, leading to destruction of the dorsal somatic element (D2-D3), with impairment of the posterior wall of the thecal sac and multiple osteolytic lesions in the cervical axial skeleton” (Fig. 2).

Bone scintigraphy revealed hypocaptant lesions compatible with multiple myeloma, with no evident metastasis of the gastric neoplasm. Abdominal echography did not show hepatic metastasis.

The patient received a definitive diagnosis of synchronous multiple primary neoplasms, associating a K light chain multiple myeloma in Durie-Salmon

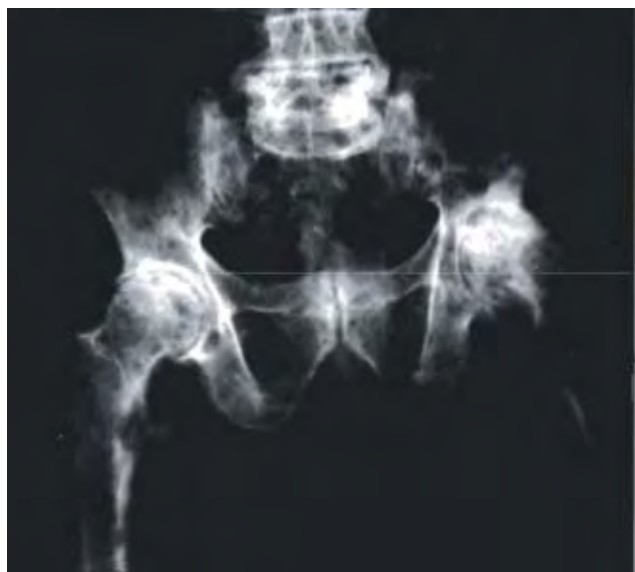

FIG. 1 A

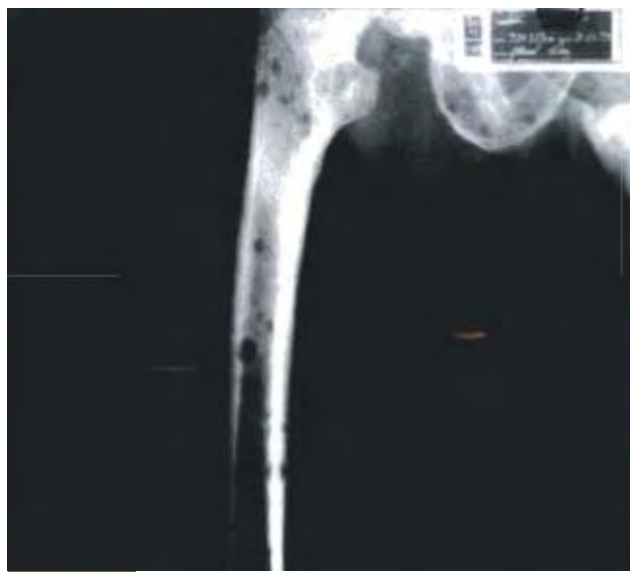

FIG. 1 B

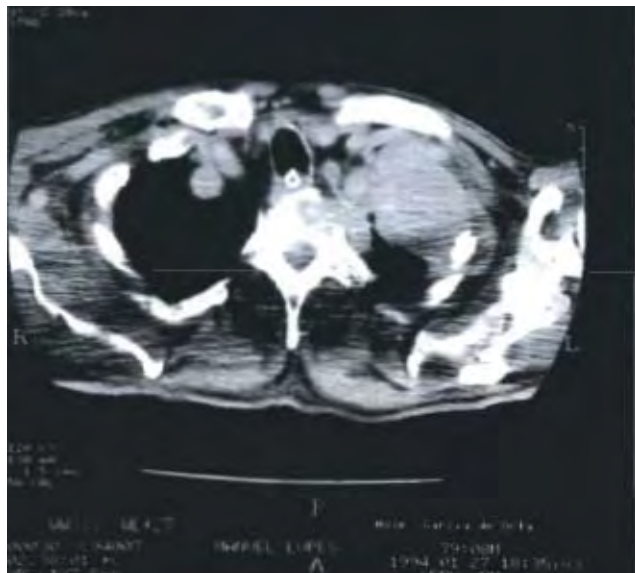


FIG. 2

stage III B, and poorly differentiated gastric adenocarcinoma.

Hypercalcemia therapy was introduced, with hydration, clodronate disodium and furosemide. Therapy was also initiated with melphalan (10 mg/day) and prednisone (1 mg/kg for 4 days), associating ranitidine and sucralfate as prophylactic measures for the digestive hemorrhage. The appearance of hematemesis necessitated the suspension of the corticoids, with transfusion support and sclerosis of the ulcerated gastric lesion with polidocanol, but without results. The surgical approach to gastric neoplasm, evaluated at the start and during the hemorrhagic episode, was made unfeasible by the poor general state of the patient, who died on the 28th day of hospitalization, following recurrent digestive hemorrhage.

Autopsy showed multiple osteolytic lesions, namely on the ribcage, compatible with multiple myeloma; stomach with ulcerated lesion of the gastric fundus, compatible with adenocarcinoma; enlarged kidneys, and poor corticomedullary definition, suggestive of acute kidney failure.

Comments

The diagnostic criteria for MPN, defined for the first time by Billoth at the end of last century, were reviewed by Warren and Gates in 1932 and restructured by Moertel in 1961, who suggests the following classification:¹

- I- Multiple primary neoplasms of multicentric origin;
 - A - in the same tissue and organ
 - B - in adjacent common tissue
 - C - in the same tissue in paired organs
- II- Multiple primary neoplasms in different tissues;
- III- Association of neoplasms in group I and II.

Despite the multiple case studies published so far, there is currently no data on the incidence of MPNs. The different series present values ranging from 1.7% to 7.4%,^{2,3,4} although that the mean values do not surpass 5%.^{2,5} However, there is a unanimous consensus regarding the fact that there has been a statistically significant increase in this type of neoplasm in recent years,^{2,3,6} which cannot be attributed to the greater sophistication of diagnostic methods alone, as it is demonstrated mainly in series of autopsies.

From the etiopathological point of view, MPNs give rise to particularly interesting questions, and are considered by some authors to be an excellent model for the study of human oncogenesis.^{7,9}

It is an agreed fact that 5% to 10% of individuals with malignant neoplasm have an increased risk of further cancer, an incidence that is higher than would be expected for a population of the same age and gender.^{1,2,4,6,9}

In the current state of knowledge of oncogenesis, it is accepted that 80-90% of malignant neoplasms result from exposure to agents of environmental origin^{8,9}. The oncogenic capacity of these agents is dependent on the intensity and duration of exposure and particularities of their metabolism, and is undoubtedly modulated by predisposing factors of a genetic, family or immunological nature.^{2,5,7,8,9}

Many of these physical and chemical agents have recognized polytopic oncogenic capacity, behaving as potential inducers of neoplasms in different organs and tissues.^{9,10} From this perspective, substances such as tobacco, a simultaneous risk factor for cancers of the lung, oropharynx, kidneys, bladder and pancreas, or asbestos, which related to neoplasms of the pleura and of the lung, will probably play a significant role in the genesis of MPN.

Iatrogenic etiology plays an important role in the occurrence of metachronous neoplasms. Individuals submitted to chemotherapy with alkylating agents or radiotherapy for neoplastic disease present an increased risk of second neoplasm, which is supported in the literature.^{1,3,8,10,11,12} Alterations in the DNA struc-

ture induced by radiation or cytostatic drugs appear to be the factor that triggers cell mutagenicity.¹⁰

Heredofamilial susceptibility to MPNs has been studied intensively, and countless diseases have been described that predispose members of the same family to synchronous and metachronous neoplasms.^{7,8,13,14,15,16} Whether because the profile of some of these diseases includes pre-neoplastic lesions, such as family polyposis of the colon, Peutz-Jeghers syndrome and Recklinghausen's neurofibromatosis, or for less clear reasons, as occurs in retinoblastoma, Lynch syndrome or Fanconi syndrome.

The longevity of the individual and the prognosis of the first neoplasm are determining factors for appearance of a second neoplasm, particularly if metachronous.^{2,17}

Although exposure to environmental agents such as pesticides, asbestos, petroleum derivatives and ionizing radiation is related to an increased risk of incidence of multiple myeloma,¹⁸ and despite the fact that some chemical compounds, such as the nitrosamines, present a close etiological relationship with gastric neoplasm¹⁹, in the clinical case reported there is no evident correlation between the two types of neoplasm, in light of the etiopathogenic factors discussed, an association that we consider fortuitous.

During the initial phase of its study, this clinical case raised some diagnostic problems.

The diagnostic hypothesis of multiple myeloma or of occult neoplasm with bone metastasis was considered because of the diffuse osteolytic lesions. This second hypothesis was reinforced by the presence of the left supraclavicular tumor, which could correspond to Troisier's sign, characteristic of gastric neoplasm secundarization.

Surprisingly, subsequent studies confirmed the existence of the two associated pathologies, with the particularity that the supraclavicular tumor is a plasmocytoma and not gastric neoplasm metastasis, as would be more logical to assume.

Finally, it is necessary to emphasize both the rarity of the type of myeloma and the rarity of the association of neoplasms detected in the case described. In the review performed, of both isolated cases of MPN and case studies, we only found three references to the coexistence of multiple myeloma with solid neoplasm, and these two types of tumor only coincided in one of them. ■

Acknowledgements

To Drs. Paula Borralho and Fernando Cunha, from the Pathological Anatomy Service, and to Dr. Piedade Ramos of the Clinical Pathology Service of HGO, for their support in the study of this case.

References

1. Moertel GG Multiple primary malignant neoplasms. Historical perspectives. *Cancer* 1977; 40 (Suppl.) 1786-1792
2. Giron CG, Redondo E. Neoplasias múltiplas. Estudio de 36 casos de série autópsica (1966-1985) *Rev Clin Esp* 1988; 182(3):137-142.
3. Watanabe S, Kodama T et al. Multiple primary cancers in 5456 autopsy cases in the National Cancer Center of Japon. *JNCI* 1984; 72; 1021-1027.
4. Bordin GM, Key CR, McQuad CF et al. Multiple primary cancers. Relative risk in New Mexico's triethnic population. *Cancer* 1977; 40 (suppl): 1793-1800.
5. Swaroop VS, Winaver SJ, Lightdale CJ et al. Six primary cancers in individuals. Report of four cases. *Cancer* 1988; 61(6): 1253-1254.
6. Cahan WG. International Workshop on multiple primary cancers. Introductory remarks. *Cancer* 1977; 40 (suppl.): 1785.
7. Mulvihill JJ, McKeen EA. Genetic of multiple primary tumors. A clinical etiologic approach illustrated by three patients. *Cancer* 1977; 40 (suppl.): 1867-1971.
8. Strong LC. Genetic environmental interactions. *Cancer* 1977; 40 (suppl.): 1861-1866
9. Wynder FL., Mushinki MH, Spivak JC, Tobacco and alcohol consumption in relation to the development of multiple primary cancers. *Cancer* 1977; 40 (suppl.); 1872-1878.
10. Ogden GR. Second Malignant tumors in head and neck cancer. Commoner then elsewhere. *Br Med J* 1991; 302; 193-194.
11. Caldwell GG. Second Malignancies as delayed result of therapy. *Cancer* 1977; 40 (suppl.); 1952-1953.
12. Cabrita M, Santos C, Jerónimo J, Malhado JA. Neoplasias Metacrónicas. Três tumores primários malignos no mesmo doente. *Geriatrics* 1993; 51 (VI): 5-7.
13. Love RR. Small Bowel Cancers. B-Cell Lymphatic Leukemia and six primary cancers with metastases and prolonged survival in the cancer family syndrome of Lynch. *Cancer* 1985; 55:499-502.
14. Helton KJ, Fletcher B, Kun LF et al. Bone tumors than osteosarcoma after retinoblastoma. *Cancer* 1993; 71: 2847-2853.
15. Dias JLR, Pereira JP, Nunes JL, Carcinomas síncronos do cólon e recto. *Boletim do Hospital Pulido Valente* 1992; 3:187-190.
16. Tripp MR, Morgan TR, Sampliner RE et al. Synchronous neoplasms in patients with diminutive colorectal adenomas. *Cancer* 1987; 60:1599-1603.
17. Mitsudomi T, Watanabe A, Matsusaka T et al. A clinicopathological study of synchronal multiple gastric cancer. *Br J Surg* 1988; 76: 237-240.
18. Salmon SN, Cassady JR. Plasma cell neoplasms. In: *Cancer Principals & Practice of oncology*, 4th Edition. J. B. Lippincot Co., Philadelphia 1993.
19. Winaver SJ. Neoplasms of Stomach. In: *Cecil-Textbook of Medicine*. 19th Edition, Saunders, Philadelphia.